

BONE DEVELOPMENT AND STRUCTURE
IN NORMAL CHILDREN

By

Gregory Joseph Bachhuber

and

William Thomas Mautz

A Thesis Submitted For The Degree of
Doctor of Medicine

University of Wisconsin
1940

487759

AWMP
B1234
1940

SEP 13 1940

~~AWM~~
~~B1234~~

University of Wisconsin Library

Manuscript Theses

Unpublished theses submitted for the Master's and Doctor's degrees and deposited in the University of Wisconsin Library are open for inspection, but are to be used only with due regard to the rights of the authors. Bibliographical references may be noted, but passages may be copied only with the permission of the authors, and proper credit must be given in subsequent written or published work. Extensive copying or publication of the thesis in whole or in part requires also the consent of the Dean of the Graduate School of the University of Wisconsin.

This thesis by *Gregory Joseph Bachhuber and William Thomas Thant* has been used by the following persons, whose signatures attest their acceptance of the above restrictions.

A Library which borrows this thesis for use by its patrons is expected to secure the signature of each user.

NAME AND ADDRESS

DATE

OUTLINE

	<u>Page</u>
I. Problem - - - - -	1
II. Material and Procedure- - - - -	1
III. Results and Discussion- - - - -	2
A-P of hands - - - - -	2
Discussion of hands - -	10
A-P of elbows- - - - -	11
Lateral of elbows- - - - -	13
Discussion of elbows- -	13
A-P of shoulder- - - - -	14
A-P of pelvis- - - - -	15
Discussion of pelvis- -	17
P-A of knee- - - - -	17
Lateral of knee- - - - -	20
Discussion of knee- - -	21
Oblique of foot- - - - -	21
Lateral of foot- - - - -	25
Discussion of foot- - -	27
General discussion - - - - -	27
IV. Comments from the literature- - - -	28
V. Bibliography- - - - -	32

With four plates and two tables

The Problem

The purpose of this thesis is to study the skeletal form and structure of a group of normal children of approximately the same age, as revealed by the x-ray.

Material and Procedure

The material studied included three boys and three girls. B was a white male of 8 years 2½ months who was 51 inches tall and weighed 55 pounds. E was a white male of 8 years 2 months who was 49¼ inches tall and weighed 58 ¾ pounds. H was a white male of 8 years and 2 months who was 50 inches tall and weighed 67 pounds. M was a white female of 9 years 1½ months who was 52 inches tall and weighed 62 pounds. RH was a white female of 9 years 1½ months who was 51½ inches tall and weighed 58 pounds. O was a white female of 9 years 7 months who was 52 inches tall and weighed 61½ pounds. The subjects were all in good physical condition. M and H had bilateral indirect incomplete inguinal herniae.

The views and the statistics for the various views are as follows:

P-A of hands

Male----	50ma	106v	40 in.	0.2s.	Detail screen
Female--	"	102v	"	"	" "

A-P of elbows

Male----	50ma	120v	"	"	" "
Female--	"	116v	"	"	" "

Lateral of elbow--right

Male----	50ma	124v.	40 inc.	0.2s.	Detail screen
Female--	"	120v.	"	"	" "

A-P of shoulder--right and left

Male----	50ma	134v.	40 inc.	0.2s.	Detail screen
Female--	"	130v.	"	"	" "

P-A of knees

Male----	50ma	138v.	40 inc.	0.2s.	Detail screen
Female--	"	134v.	"	"	" "

Lateral of knee--left

Male----	50ma	134v.	40 inc.	0.2s.	Detail screen
Female--	"	130v.	"	"	" "

Oblique of foot--plantar flexion and inversion

Male----	50ma	128v.	40 inc.	0.2s.	Detail screen
Female--	"	124v.	"	"	" "

Medio-lateral of feet

Male----	50ma	128v.	40 inc.	0.2s.	Detail screen
Female--	"	124v.	"	"	" "

A-P pelvis

Male----	50ma	136v.	40 inc.	1.0s.	Par-speed screen
Female--	"	132v.	"	"	" "

This is a total of ten x-ray plates of each child.

Results and Discussion

The following descriptions of bones are as they are seen in the x-ray plates, and the third dimension is not taken into consideration.

A-P of hands

The distal end of the radius flares on both sides. As it flares, trabeculae lead longitudinally to the epiphyseal line. There is some fine cross-trabeculation of

the end of the shaft. One male (H) shows a rather dense white band at the distal end of the shaft. This is less marked in the other males and relatively absent in the females. The radial epiphysis is a wedge, with rounded edges and the base directed radially. The proximal and distal surfaces are of denser consistency. Some show a Y-shaped marking of density. The epiphysis is better adapted and more closely applied to the end of the shaft in the females.

The distal end of the ulna flares, especially on the radial side. There is some longitudinal trabeculation of the shaft. The end is ragged markedly so in the males. In the males, the epiphysis is smaller than the end of the shaft and varies from a small irregular circle to a flattened disc; the approximation varies with the size of the epiphysis but is not closely applied in any. In the females the ulnar epiphysis is an irregularly S-shaped to a flattened lozenge-shaped body. The cortex is more dense and the epiphysis is more closely applied. One female (RH) shows a separate center for the ulnar styloid; this is a small ovoid to circular body projecting partly from the middle of the distal side of the epiphysis.

In two of the males the navicular is a roughly triangular figure with rounded edges and is somewhat concave adjacent to capitate. In one male (H) it is smaller but has the same general appearance. In the females the bone appears larger, the concavity adjacent to the capitate is

more marked; it is denser adjacent to the capitate; it is more closely applied to the surrounding bones; and in one female (O) it is flattened adjacent to the greater multangular.

The lunate is an ovoid bone slightly overlapping the capitate, and showing density suggesting a shelf adjacent to the capitate in one male (E) and better marked in all the females. It is larger in the females, more closely applied to the other carpals, and partially overlaps the radial epiphysis.

The triquetral is a rounded right triangle with the right angle adjacent to the lunate and the hypotenuse on the ulnar side. It lies close to the hamate and is somewhat adapted to it in the males, and more so in the females. It is larger and the angle is more pronounced in the females than in the males. One female (M) seems to have a small ossified fragment extending several millimeters toward the ulna and more marked on the left (pisiform?).

One female (O) shows a pisiform represented by a circular shadow superimposed on the ulnar side of the triquetral.

In one female (RH) there is an irregular center of density lying between the capitate and lunate and partially underlying the triquetral.

The greater multangular, absent in one male (H), is represented by a rounded quadrilateral with flattened surfaces facing the first metacarpal, lesser multangular,

and navicular and partially overlapping the lesser multangular. One male (E) shows slight prominence of the angle toward the base of the second metacarpal. This prominence is larger and better defined in the females, especially (RH) and (O), and in the latter it overlies the base of the second metacarpal. One female (O) presents a concave facet adjacent to the epiphysis of the first metacarpal.

The lesser multangular in one male (B) is roughly a circle with less curvature adjacent to the second metacarpal and hamate and partially overlying the greater multangular. In one male (H) it is a very small circle in one wrist and absent in the other. In the females it is larger and better adapted to the capitate, second metacarpal, and navicular. In one female (O) there is a pointed prominence extending into the concavity of the head of the second metacarpal. Except in one male (H) the cortex shows a ring of compact bone incomplete on side facing greater multangular.

The capitate is roughly a quadrilateral with rounded corners flat on sides adjacent to hamate (with slight overlapping) and base of third metacarpal. The corner adjacent to the lesser multangular and base of the second metacarpal is flattened and modified for contact. Two of the males (B and E) show a notch on the middle of the radial side and in one (H) a rarefaction is seen at this point. In the females, especially one of them (RH), there

is longitudinal and transverse trabeculae noticeable in the bone, but in the males there is no definite pattern.

The hamate is fundamentally a right triangle with the right angle adjacent to the capitate and base of the fourth metacarpal. The side adjacent to capitate is convex and overlaps the capitate. The hypotenuse is slightly concave and adapted to the triquetrum. In the females the angles are more acute than in the males; the bone is somewhat larger; and the distal surface is modified for the bases of the fourth and fifth metacarpals.

The epiphysis of the first metacarpal in the male is convex proximally and flattened distally. It is smaller in one male (H) than in the other two (B) and (E) and is closely applied in none. In the females the epiphysis is larger; the proximal surface is better adapted for the joint with multangular; and it is better adapted to the end of the shaft. The proximal end is flattened and in two of the males (E and B) there is slight radial lipping. The shaft of the first metacarpal is somewhat narrower in the middle and shows ulnar concavity. There is a small notch in the radial side near the bulbous distal end. The cortex is thicker on the ulnar than the radial side; the distal portion of the shaft contains some coarse trabeculae which are primarily longitudinal; and the distal end is spongy.

The base of the second metacarpal is expanded especially toward the base of the third metacarpal and the

capitate. Where there is a lesser multangular, the proximal surface is concave; this is more marked in the females, especially in one (O). There is a notch on the radial side near the proximal end. There is some irregularity of the base on the side adjacent to the third metacarpal. The shaft is narrower in the middle than the ends. There is greater ulnar than radial concavity except in one female (O). The distal end is tilted to the radial side. The epiphysis is oval and closely applied centrally and somewhat closer applied in the females than in the males. It is more pointed on the radial side of the epiphysial line. Some trabeculae extend into the ulnar projection of the base of the second metacarpal.

The proximal end of the third metacarpal is club shaped. In two of the males (H and E) there is minimal adaptation to adjacent bones. In one male (B) and all the females the proximal surface is flattened and shows a shelf which suggests a concavity adjacent to the capitate. This is most marked in one female (O). There is adaptation to the bases of the second and fourth metacarpals which is slight in the males and more marked in the females, especially in one (O). The adaptation takes the form of irregularity and overlapping. The shaft is narrower in the middle and flares distally especially on the radial side. The concavity of the radial side is more marked than of the ulnar and is closer to the distal end which is irregular. The epiphysis is as the epiphysis in the

second metacarpal but more ovoid. The cortex extends to the end of the flare on the radial side.

The proximal end of the fourth metacarpal is flat and tilted toward the ulnar side. The base is irregular on the side adjacent to the third base especially in the females. The ulnar side overrides the base of the fifth metacarpal. Both sides of the shaft are concave but the concavity on the radial side is nearer the distal end. The distal end is cupped somewhat. The epiphysis is roughly circular but flattened on the base and the ulnar side.

The proximal end of the fifth metacarpal is tilted radially and flattened adjacent to the hamate. The flattening is more marked in the girls. There is a small notch on the ulnar side near the proximal end which is absent in one male (H) and one female (M). There is overriding of the fourth base. The ulnar surface is slightly convex and the radial surface is concave. There is slight radial flaring at the distal end. The distal end is cupped for the epiphysis. The epiphysis is oval but flattened on the ulnar side. The cortex is thicker but less dense on the ulnar side.

The epiphysis of the first phalanx of the first digit is concave proximally. The epiphyseal surface toward shaft is irregular and is not closely applied. The end of the shaft is wavy and angular. The shaft tapers toward the distal end and the ulnar side of the end bulges. One female (O) shows an angulation on the radial side of the distal end. There is a small notch in the radial side near the distal

end. There is an ulnar concavity of the shaft. The cortex is heavier on the radial side and there are a few coarse longitudinal trabeculae.

The epiphysis of the first phalanx of the second digit is concave and dense on the proximal side. The proximal end of the shaft is irregular, angulated, and flares to the ulnar side. The radial concavity is somewhat greater. The distal end of the shaft tapers slightly and there is a small distal concavity, more marked in the females (especially O), for articulation with the second phalanx. The cortex is poorly defined and there are numerous coarse trabeculae.

The remainder of the proximal phalanges answer to essentially the same description except for differences in size and those given here. The epiphysis of the first phalanx of the third digit is less thick on the radial side than before and the remainder of the proximal epiphysis are of uniform thickness. There is uniform flare of the bases of the phalanges.

The epiphyses of the second phalanges of the second, third, fourth, and fifth digits are convex proximally and flattened and irregular distally to fit the shafts of the phalanges. The distal ends flare slightly to the radial side. The distal ends are flat. There is a slight notch in the radial side of the distal end in one male (E) and on both sides in one female (M).

The epiphysis of terminal phalanx of the first digit is convex on the proximal side and applied rather closely to the

shaft. The shaft is irregular at the proximal end and tapers distally. The distal end is bulbous especially on the ulnar side. The shaft is curved to the radial side.

The remaining terminal phalanges have epiphyses with convex proximal sides and flattened irregular distal sides. The shaft tapers from an angular base to a bulbous tip.

Discussion of hands

The bones of the females, especially the carpals, are larger than those of the males. The proximal ends of the metacarpals of the females are larger and are better adapted than the males. Each given age group shows several stages in maturation and the distribution in the females is wider. The most marked variations are in the carpal bones. One male (H) has several missing centers but later maturing centers are about on a par with the other males. One female has a pisiform and the presence of a pisiform in the other two females is questionable. One female shows an ulnar styloid apparently as a separate center of ossification.

According to Todd's classification, the bone ages of the subjects are as follows: Two males (E and H: both really 8 years 2 months old) were classified as 7 years 6 months; One male (B: really 8 years 2½ months old) was classified as 7 years 9 months; two females (M and RH: both really 9 years 1½ months old) were classified as 8 years 6 months; and one female (O: really 9 years 7 months old) was classified as 9 years. It must be remembered that Todd's classification is based on the upper 20%.

See Figures 1 and 2, Plate I.

Plate I

Figure 1

Female left hand (RH)

1. Radius
2. Epiphysis of radius
3. Ulna
4. Epiphysis of ulna
5. Navicular
6. Lunate
7. Triquetral
8. Greater multangular
9. Lesser multangular
10. Capitate
11. Hamate
12. Epiphysis of first metacarpal
13. First metacarpal
14. Second metacarpal
15. Third metacarpal
16. Fourth metacarpal
17. Fifth metacarpal
18. Center for ulnar styloid

Figure 2

Male left hand (B)

1-17 inclusive--As Figure 1.

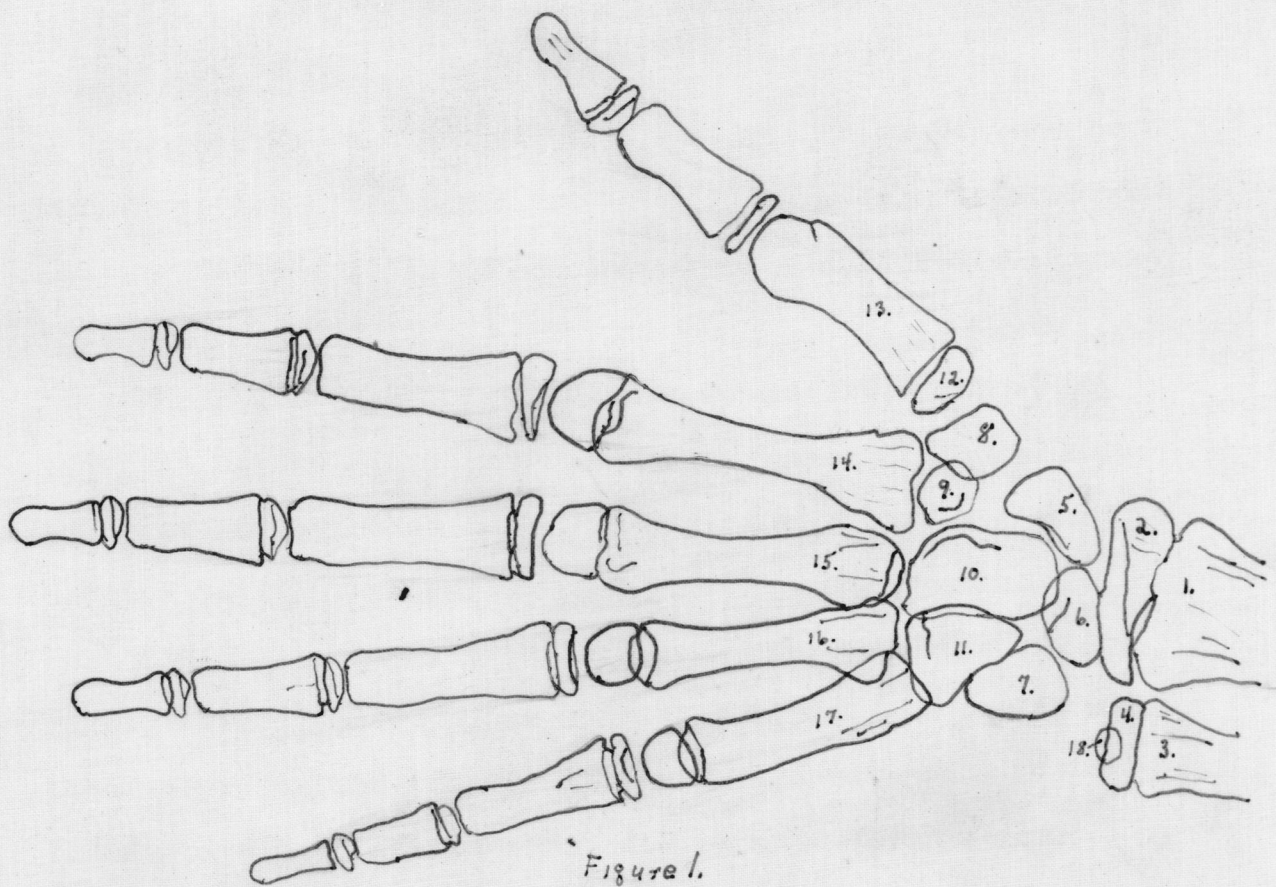


Figure 1.

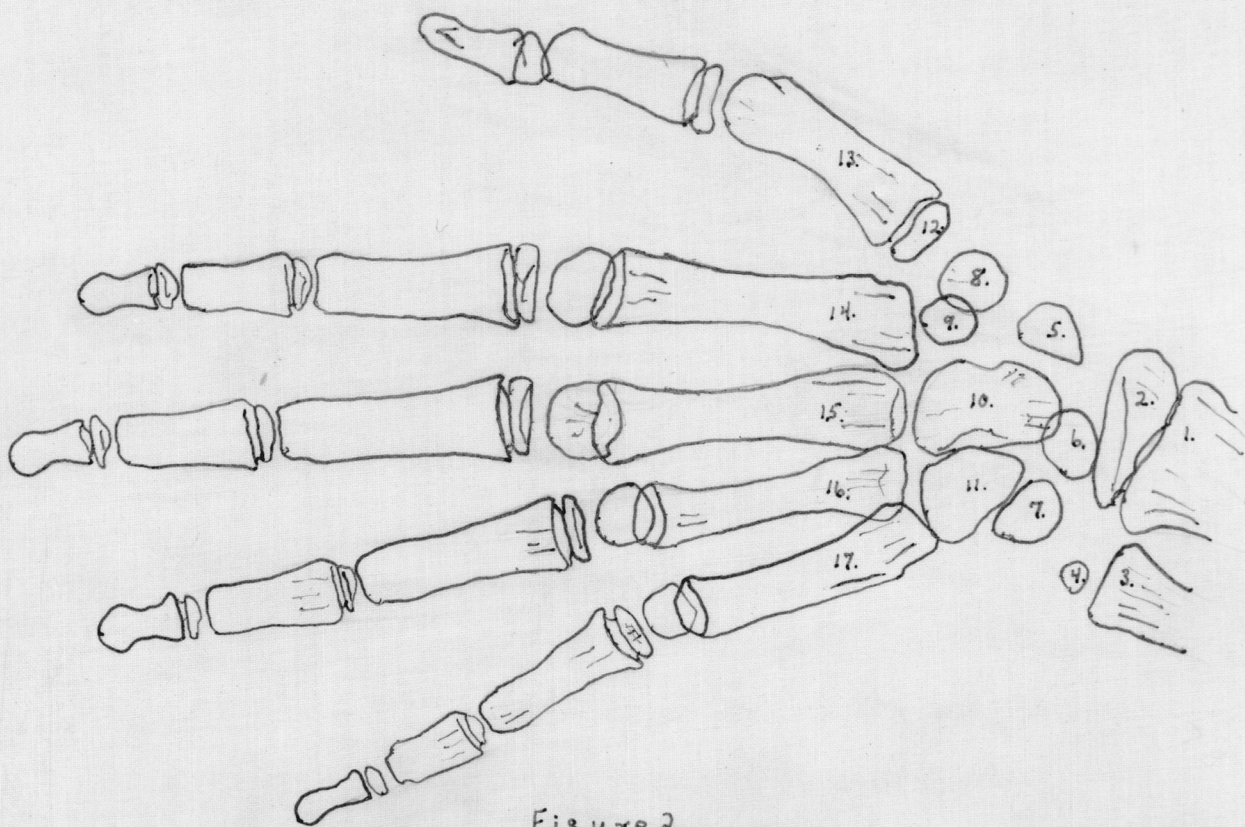


Figure 2.

A-P of elbows

The shaft of the humerus flares at the distal end most marked on the medial side but the lateral flare is shorter causing the end of the diaphysis to be tipped somewhat laterally.

The medial humeral epicondyle is an ovoid structure adjacent to the medial condyle. It is smaller in one male (H) than in the other males. It is larger and more closely applied in the females.

The capitulum is a quadrilateral mass of bone lying partly superimposed on the lateral condyle. It is thicker laterally. In the females it is larger, extends further over the diaphysis of the humerus, and is more obscure along its upper margin.

The lateral humeral epicondyle is present in none of the males, and is present in one of the females (O) and possibly in a second female (RH) on the right side. It is a small hazy irregular shadow just lateral to the juncture of the capitulum and the lateral condyle.

The trochlea of the humerus is present in two females (M and O). It is represented by a hazy irregular cauliflower-like mass applied to the medial condyle in (M). In (O) it is larger and more distinct.

The cortex and medulla of the shaft of the humerus are clearly differentiated. As the shaft flares, about 4.5 cm. from the distal end, trabeculae leave the cortex and follow a longitudinal path into the condyle of the same side of the

shaft. There are also some heavy trabeculae crossing toward the opposite side; these are most numerous from lateral to medial and are in the next 4.5 cm. of bone above the olecranon fossa. There is a dense crescent-shaped area located on the lateral margin of the olecranon fossa. There is also a less well-marked crescent on the medial side of the fossa. The floor of the olecranon fossa appears quite thin and in one female (O) there is a definite supratrochlear foramen present. There are fine cross trabeculations distal to the olecranon fossa which extend into the condyles.

The shaft of the ulna flares proximally into the coronoid process and then continues into the olecranon which is short and blunt. The olecranon epiphysis is present in all the females and is seen as a small flattened ovoid close to the end of the olecranon. It is seen in none of the males in this view. There is distinct cortex and medulla in the shaft and the cortex extends to the coronoid process. There is some longitudinal trabeculation of the shaft about the coronoid which fades into the olecranon.

The proximal end of the radius flares laterally and bulges medially. The bicipital tuberosity is outlined on the medial aspect of the shaft. There is angulation of the neck with the head directed laterally. The epiphysis is a dense discoid mass narrower than the end of the shaft to which it is adapted. It is larger and more closely applied in the females one of whom (O) shows definite lipping of epiphysis over end of shaft. There is some longitudinal trabeculation in the head. The cortex is diffuse over the bicipital tuberosity.

Lateral of elbow

This view was taken to show the olecranon and its epiphysis.

The olecranon epiphysis appears as a small hazy shadow in only one male (B). It is seen in all the females as an oval shadow (largest in O) not closely applied to the olecranon. The flexor side of the olecranon is longer than the extensor side, especially in the females.

In one of the females (M) on the extensor surface of the proximal end of the ulna the cortex fans into trabeculae which follow an arcuate path to the end of the olecranon process. From the flexor cortex some trabeculae extend into the coronoid. A few arch toward the extensor surface and end in the olecranon. The coronoid notch is lined with fairly dense bone with fine trabeculae radiating away from the notch.

Discussion of elbows

The medial epicondyle of the humerus of the female is generally larger and more closely applied to the condyle than in the male. The trochlea is present in two of the females but in none of the males. The capitulum is larger and more closely applied in the females. The lateral epicondyle of the humerus is present bilaterally in one female and unilaterally in another. A supratrochlear foramen is present in one female. The olecranon epiphysis is present in all the females but is seen in one of the males (B) in lateral view. The proximal radial epiphysis is better developed and more closely applied in the females. The "carrying angle" or

Plate II

Figure 3

Male A-P right elbow (B)

1. Humerus
2. Capitulum
3. Medial humeral epicondyle
4. Ulna
5. Coronoid
6. Olecranon
7. Radius
8. Bicipital tuberosity of radius
9. Epiphysis of radius

Figure 4

Female A-P right elbow (O)

- 1-9 as in Figure 3
10. Lateral epicondyle
11. Trochlea
12. Supratrochlear foramen
13. Olecranon epiphysis

Figure 5

Male lateral right elbow

- 1-7. as in Figure 3
8. Epiphysis of radius
9. Olecranon epiphysis

Figure 6

Female lateral right elbow

- 1-9. as in Figure 5

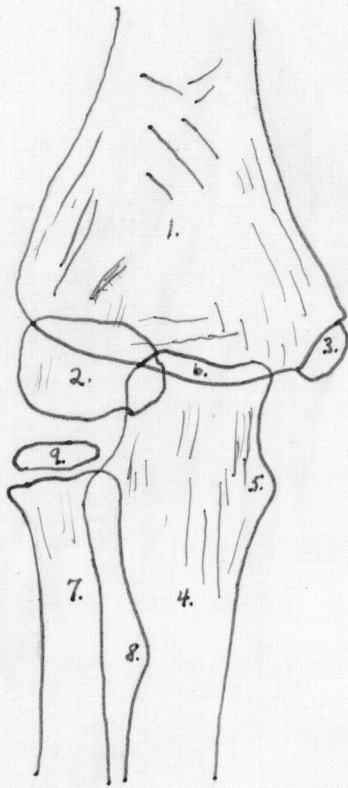


Figure 3.

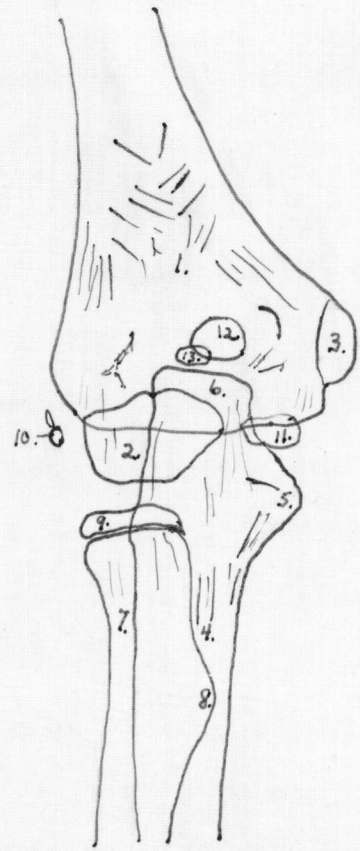


Figure 4.

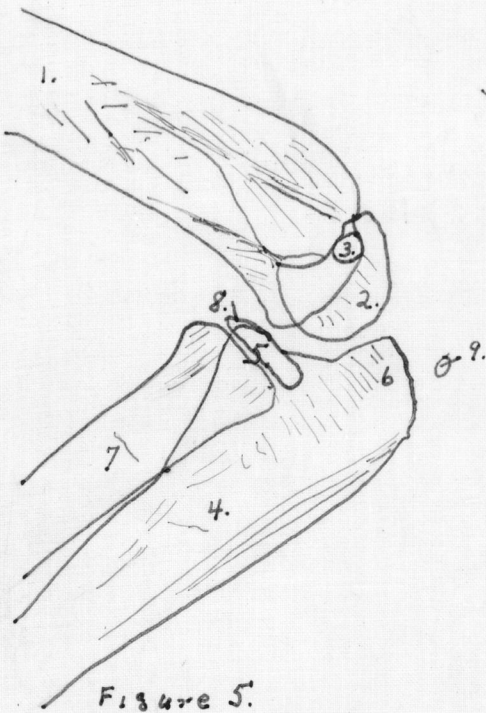


Figure 5.

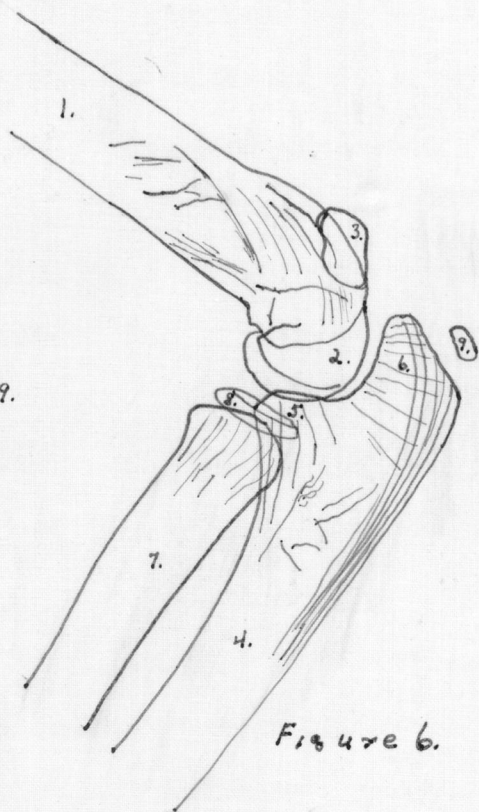


Figure 6.

angle of the arm with the fore-arm is greater in the female.

See Plate II, Figures 3, 4, 5, and 6.

A-P of shoulder

The proximal end of the humerus flares medialward and seems to have a triangular cuplike end for articulation with the epiphysis. The epiphysis has a double curvature proximally; a larger one representing the head and a smaller lateral one representing the greater tuberosity. Part of the distal margin of the epiphysis has a dense band along its edge. The cortex is well differentiated in the shaft of the humerus. From both cortices, but more on the medial side, trabeculae fan toward the head.

The end of the acromion is rough in all but one male (E). There are coarse trabeculae running longitudinally in the acromion and some interdigitate especially near the tip.

The coracoid is represented by an ovoid density near the base of the acromion which projects above the acromion in one male (B) and one female (O).

The glenoid tubercle shows as a small pointed projection at the lower end of the glenoid fossa and is somewhat more prominent in the females.

A number of heavy trabeculae run across the scapula from the base of the acromion toward the vertebral border of the bone.

The clavicle is expanded and bulbous medially and has a squared-off lateral end. The cortex and medulla are well differentiated in the shaft but the ends are spongy. One

female (RH) has a small dense spot two fifths the distance from the lateral end to the medial end.

There is essentially no difference in male and female.

A-P of pelvis

The ilium shows dense bone along pelvic margin from posterior inferior spine to the ilio-ischial junction. A second dense band follows the upper margin of the acetabulum and is backed by numerous transverse trabeculae. The lateral margin of the crest is rough. There are some fine trabeculae running parallel to the iliac crest. In the medial third of the ilium the trabeculations are vertical. There is a similar band parallel to the edge of the ilium in the lateral fifth. There are a few trabeculae radiating from the pelvic margin.

The ilio-ischial space is several millimeters wide.

In the ischium a roughly vertical band of density extends down from the body medial to the acetabulum into the medial portion of the superior ramus. Just lateral to this there is a curved dense line lining the acetabulum. This line is traversed by numerous short radial trabeculations. The superior ramus joins the inferior ramus in a more rounded angle in the male than in the female. There are some fine longitudinal trabeculae in the superior ramus of the ischium, and a few scattered longitudinal lines are seen in the inferior ramus.

The upper margin of the superior ramus of the pubis shows a line of dense cortex. The symphysis is somewhat irregular. The juncture of the inferior ramus of the pubis

with the inferior ramus of the ischium is marked by a fusiform swelling in the females and by a tubercle or overlapping in the males.

The shaft of the femur angulates medially at the proximal end to form the neck. The proximal end is roughened adjacent to the epiphysis and has a bulge on the medial side below the epiphysis. The epiphysis is roughly hemispherical and is closely applied to the end of the neck. There is a small fault in the supero-medial margin. The greater trochanter is roughly a right triangle with the right angle set into the lateral side of the angulation of the shaft. One of the females (M) shows a hook-shaped projection on the superior angle. Another female (RH) shows a small separate hazy center just above the superior angle. The greater trochanter is smaller and more rounded in the males.

The lesser trochanter appears as a pyramidal projection on the medial side of the shaft just below the angle with the neck. It varies in size in different individuals. There is no separate center.

The cortex of the shaft is thick and distinct. On the medial side it extends to the middle of the neck. In the region of the lesser trochanter it is less compact. Trabeculae begin to fan from the medial cortex at about the level of the lesser trochanter; these curve laterally toward the greater trochanter. A second group of heavy trabeculae leave the medial cortex above the lesser trochanter and extend upward, fanning as they go, and end in the midportion of the epiphysial line.

Plate III

Figure 7

Male A-P right hip (E)

1. Ilium
2. Ischium
3. Pubis
4. Pubic symphysis
5. Acetabulum
6. Femur
7. Epiphysis of head
8. Lesser trochanter
9. Greater trochanter
10. Tubercle at pubo-ischial
 junctionure

Figure 8

Female A-P right hip

1-9. as in Figure 7

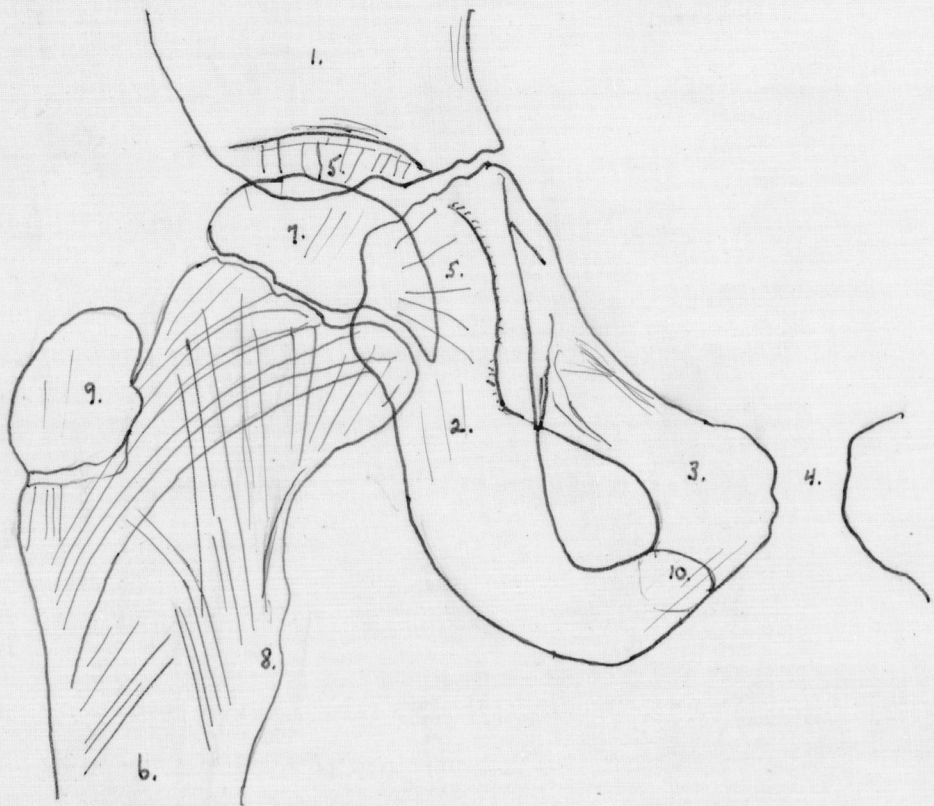


Figura 7.

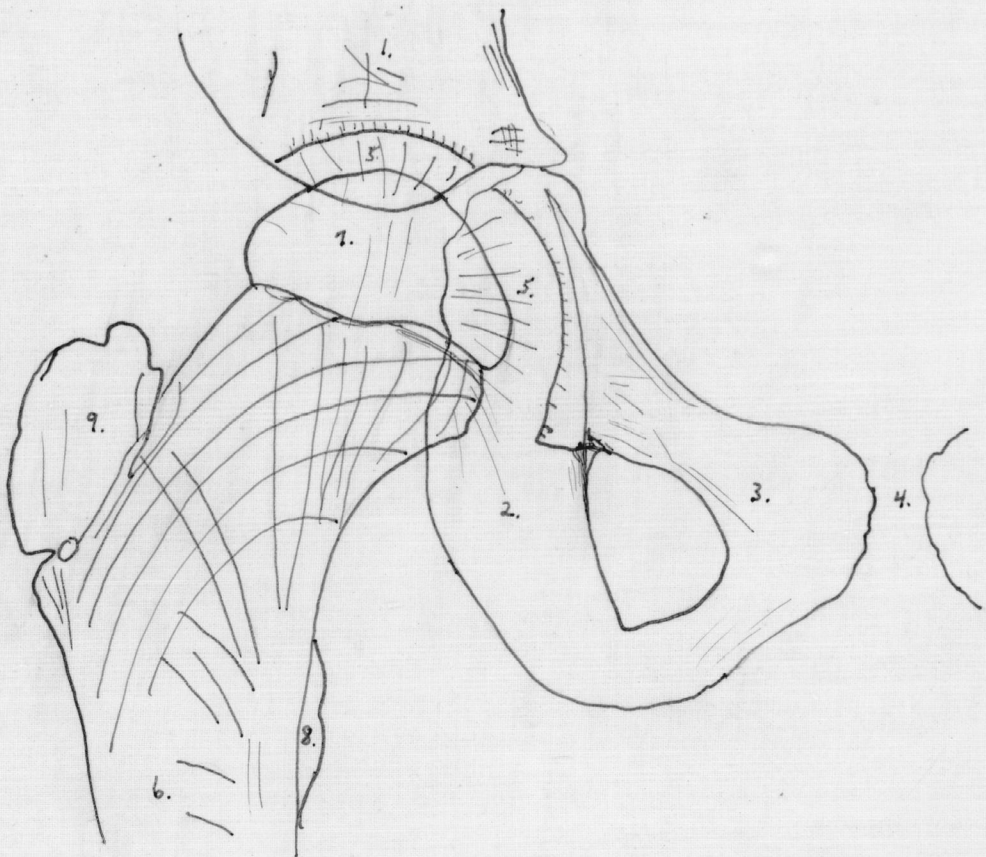


Figure 8

The lateral cortex of the shaft flares somewhat laterally as it approaches the greater trochanter from below. As it flares it gives off two sets of trabeculae, one continuing longitudinally to the base of the greater trochanter and the second extending upward and curving medialward some ending in the epiphysial line but many ending on the medial side of the head. The intersections of trabeculae appear to take place at about right angles.

Discussion of pelvis

The greater trochanter is larger and more angular in the females, one of whom has a spur at the superior angle and a second of whom has a small separate center at the superior angle. The juncture of the inferior rami of the pubis and ischium is marked by a fusiform swelling in the females and by tubercles in the males. The superior ramus of the ischium seems to form a sharper angle with the inferior ramus in the females and a more curved surface in the males.

See Plate III, Figures 7 and 8.

P-A of knee

The distal end of the femur flares. The end of the shaft has three gross curves: a medial and a lateral convex and a middle concave. It is finely irregular and adapted to the epiphysis. The distal end is marked transversely by a dense band. The epiphysis is closely approximated to the diaphysis especially in the females and the proximal surface is marked by a narrow dense band. The distal surface is

marked by two convex prominences with a concavity between them (condyles). The medial condyle is thicker causing the end of the epiphysis to tilt more laterally than the end of the shaft. The lateral aspect of the medial condyle has a small secondary convexity in one female (M) and one male (B).

The cortex and medulla of the femoral shaft are well defined. Beginning about 10 cm. above the epiphysial line, where the flaring of the shaft begins, the cortex gives rise to longitudinal trabeculae which lead to the epiphysial line. In the epiphysis, the lines continue, to end perpendicular to the articular surface. Those trabeculae from the lateral cortex form a rather distinct longitudinal band about 1.5 cm. wide just lateral to the middle of the shaft. This is most clear-cut in one female (M) and can be seen in all the others except one male (H). The central part of the shaft has few longitudinal but does show a few fine oblique interdigitating trabeculae. The lateral edge of the medial group of trabeculae has a dense vertical marking in the epiphysis in the females; this leads to the lateral edge of the convex portion of the medial condyle. The distal portion of the shaft has a few fine transverse trabeculae. The distal portion of the epiphysis shows numerous fine trabeculations parallel to the inferior surface and most numerous in the intercondylar region. In the intercondylar region finer trabeculae are seen radiating perpendicularly from the surface toward the epiphysial line.

The patella appears as a circular shadow somewhat elongated inferiorly lying a little medial to the midline of the femur in the region of the epiphysial line of the distal femoral epiphysis. It is larger in the females, and one female (RH) shows a separate fragment at the upper lateral margin of the right patella.

The proximal epiphysis of the tibia presents two concavities with an elevation between them for articulation with the femur. There is a dense layer of bone on the epiphysis adjacent to medial side of lateral femoral condyle. The distal surface is rough and concave and closely adapted to the tibia. In one male (H) the epiphysis is thicker on the medial side than on the lateral side. The shaft of the tibia flares proximally and the end of the flare is more angular on the lateral side.

The proximal tibial shaft shows well differentiated cortex and medulla. There are coarse longitudinal trabeculae in the shaft running to the epiphysial line and apparently continuing into the epiphysis especially to the medial and lateral condyles. The proximal end of the shaft shows fine transverse trabeculation. The transverse trabeculation of the epiphysis is more marked in the proximal half and is roughly parallel to the surface of the bone.

The proximal fibular epiphysis is lozenge-shaped and flattened medially and thicker laterally. It is covered by a thin shell of compact bone. The distal surface is quite irregular. The fibular shaft flares proximally and is adapted

to the irregularities of the epiphysis. There are a few longitudinal trabeculae leading from the cortex as it thins and flares. There are also a few cross trabeculations.

Lateral of knee

The distal end of the shaft of the femur flares especially posteriorly. The distal surface is grossly irregular and somewhat convex. The condyles of the epiphysis lie mostly posterior to the long axis of the femoral shaft. They are superimposed on one another and within their margins there is a dense line which appears to mark the intercondylar fossa.

The distal part of the femoral shaft shows longitudinal trabeculation more marked along the anterior surface. Many of the longitudinal trabeculae curve toward the opposite side interdigitating with similar trabeculae from the opposite side.

The patella appears as an almond-shaped bone lying off the condyles of the femur. It has curved trabeculae parallel to the anterior surface located in the anterior one third, and also radiating trabeculae from the posterior surface. The bone is longer in the girls and the internal structure is better marked.

The proximal epiphysis of tibia is roughly oval with a pointed projection on the proximal surface. The distal surface is irregular and closely applied to shaft especially in the females. One girl (M) shows a large lip extending down over the anterior margin of the tibial shaft. The proximal part of the shaft flares posteriorly. The end is rough and

Plate IV

Figure 9

A-P knee (0)

1. Femur
2. Epiphysis of femur
3. Medial condyle of epiphysis
4. Lateral condyle of epiphysis
5. Patella
6. Tibia
7. Epiphysis of tibia
8. Fibula
9. Epiphysis of fibula

Figure 10

Lateral knee (0)

- 1-9. as in Figure 9
3 and 4 superimposed

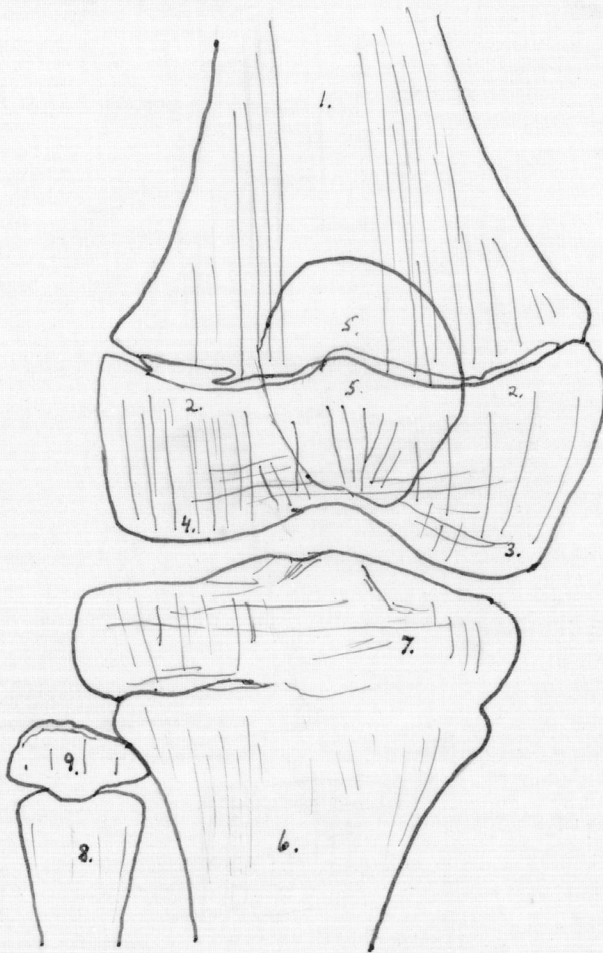


Figure 9.

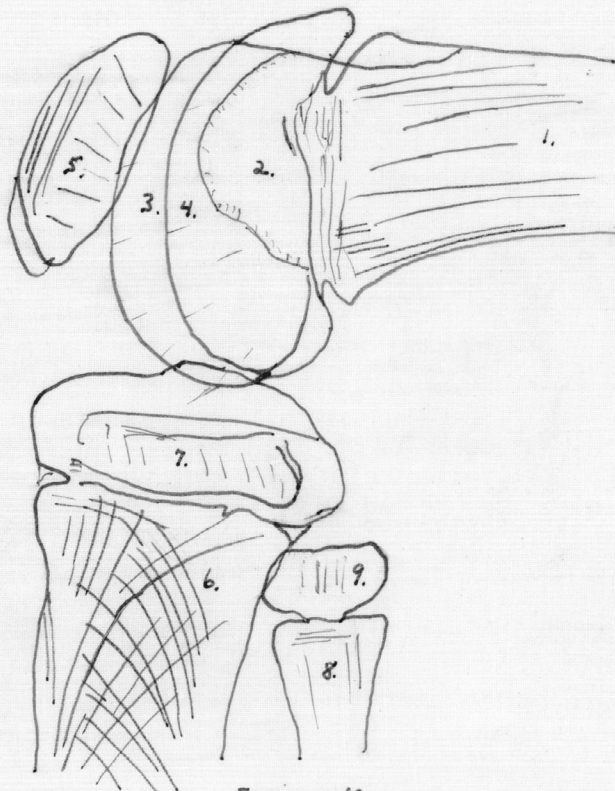


Figure 10.

adapted to the epiphysis. The anterior corner is flattened for the epiphyseal lip in one female (M).

The tibial cortex is well differentiated. Many longitudinal trabeculae end with the cortex about 1.5 cm. below the epiphysial line on the anterior surface. Posteriorly the cortex goes to the end of the shaft giving off longitudinal trabeculae as it flares. There are many trabeculae arching from the anterior cortex to the epiphysial line and the posterior tip of the shaft. Also many finer trabeculae arch from the posterior cortex to the epiphysial line and the upper part of the anterior side of the shaft.

The fibula shows nothing not already described under the P-A view.

Discussion of the knee

The structure of the knee is generally more clear in the females. The patellae of the females are larger than those of the males. One female (RH) has a fragmented patella at the superior lateral angle. One female has a lipping of the tibial epiphysis over the proximal end of the shaft anteriorly.

See Plate IV Figures 9 and 10.

Oblique of foot

The distal end of the shaft of the tibia flares especially posterolaterally. The epiphysial line is irregular and concave distally. The proximal surface of the epiphysis fits the shaft end closely. The distal surface of the epiphysis is concave except for a large inferior extension more anterior than posterior--(the medial malleolus).

The cortex of the shaft of the tibia is well differentiated. There are numerous longitudinal trabeculae extending downward, especially from the posterior side, to the epiphyseal line. The longitudinal trabeculae in the epiphysis concentrate in the malleolar process. There are a few transverse trabeculae in the lower shaft and in the epiphysis.

The fibular shaft flares distally and is irregular on the distal end. The epiphysis is an ovoid with the long axis longitudinal and with a flattened rough proximal end. The cortex and medulla of the shaft are well marked. There are some longitudinal trabeculae and a few cross trabeculae at the extreme end.

The tarsal navicular is roughly quadrilateral. The proximal surface is concave. The lateral surface is flattened adjacent to the cuboid. The distal surface shows 3 facets for the articulation with the first, second, and third cuneiform. The facets are more marked in the females. There is compact bone on the proximal and distal surfaces. The bone shows longitudinal trabeculae which fan somewhat; they continue the pattern from talus and transmit it to the cuneiforms.

The first cuneiform appears as a quadrilateral. The proximal surface is somewhat concave. The distal surface presents a notch at the medial angle adapted to the head of the second metatarsal, missing in one male (H) and generally larger in the females, and is otherwise convex for articulation with the first metatarsal. It overlaps the second

cuneiform. Longitudinal trabeculae in the first cuneiform continue the pattern of the navicular.

The second cuneiform is roughly quadrilateral. The proximal surface is concave for articulation with the navicular; distal and medial surfaces are convex; and the lateral surface is flattened. It overlaps the first cuneiform. The trabeculae are longitudinal. The bone is shorter and less well adapted to its mates in one of the males (H).

The third cuneiform is roughly rectangular, concave medially for the second cuneiform convex distally for the third and fourth metatarsals, and convex toward the cuboid. The corner adjacent to the second metatarsal is somewhat flattened. The trabeculation is irregular except for 2 dense bands roughly parallel to the sides of the bone and close to them; these are absent in two males (H and E).

The cuboid is roughly a five sided figure. The surface adjacent to the calcaneus is convex medially and concave laterally. The surface adjacent to the navicular is flattened. The surface adjacent to the third cuneiform is concave. Distally the bone presents two flattened facets for the fourth and fifth metatarsals. The lateral side is flat. There is dense bone on surfaces facing the calcaneus and the third cuneiform. There are longitudinal trabeculae and others continuing the pattern of the calcaneus toward the third cuneiform. There is an oval area of density on the navicular side of the center of the bone in one male (B). One male (H) shows no distal facets or internal structure. The structure is better in the females.

The epiphysis of the first metatarsal is discoid and has a projection into the shaft near the medial side. The shaft flares at the proximal end and the corners are angular. The distal end is bulbous especially on the lateral side. There is a fibular concavity of the shaft. There is coarse longitudinal trabeculation especially near the proximal end. There is a pseudo-epiphysis on the distal end in the males.

The proximal end of the second metatarsal flares and is tilted medialward for articulation with the first two cuneiforms. The lateral side is adapted for articulation to the third metatarsal and the third cuneiform. Medially it overlaps the first metatarsal. The distal end flares slightly and has a cupped surface. The epiphysis is oval with longer axis longitudinal. The fibular concavity of the shaft is greater than the tibial. The cortex of the shaft is heavy and well-defined. There are some coarse longitudinal trabeculae in the proximal end.

The proximal end of the shaft of the third metatarsal is slightly expanded and in most is convex adjacent to the third cuneiform. It is adapted to the second and fourth heads by shelf-like processes (not prominent in one male (H)). In one female (RH) the head is tilted laterally somewhat. There is a slight distal flaring. There is greater tibial concavity. The epiphysis and internal structure are as in the second metatarsal.

The proximal end of the shaft of the fourth metatarsal is squared and adapted to the third and fifth bases. The

distal end of the shaft is expanded, tilted laterally, and cupped to receive the oval epiphysis. The fibular concavity is greater. There are a few transverse trabeculae in the base.

The main curve of the shaft of the fifth metatarsal is a fibular concavity but proximally it is convex on the fibular side. The proximal end is expanded and the surface is flat for cuboid. The surface adjacent to the fourth base is flattened and adapted to it. The distal end is slightly expanded, tilted laterally, cup-shaped, and embraces the oval epiphysis. There are interdigitating trabeculae in the distal shaft.

In one female (RH) there is a small round shadow suggesting a sesmoid bone on the lateral side of the bulbous portion of the first metatarsal of the right foot. There is also a round density just proximal to the epiphysis of the first metatarsal and overlaid by the first cuneiform.

In another female (O) there is a small hazy shadow underlying the bulbous distal end of the first metatarsal. There is also a larger more distinct shadow just lateral to the distal end. These are interpreted as being sesamoid bones.

Lateral of foot

The talus presents a convex postero-superior surface for articulation with the tibia. The anterior and anterior part of inferior surfaces are convex for articulation with the navicular and calcaneus. The inferior surface is roughly concave but convex at its posterior end. A spur projects into this concavity. In one female (O) the posterior part of the inferior surface has a square downward projection.

overlying part of the calcaneus. In one female (RH) there are bilateral ossa trigona occupying concavities in the posterior inferior angle. The os trigonum also occurs on the right side in another female (M). These are small triangular fragments. There is heavy vertical trabeculation in the body of the bone. There are horizontal trabeculations, most marked in the upper half, running the length of the bone. There are also short fine trabeculae perpendicular to the anterior and inferior surfaces of the bone. A few coarse trabeculae extend a short distance upward and anteriorly from the anterior end of the base of the spine. There is dense cortex along the middle of the superior margin.

The superior surface of the calcaneus is grossly concave but posteriorly presents a convex facet for articulation with the talus. Anteriorly it is concave for articulation with the cuboid. The inferior surface is concave. The posterior surface of the tuber is very rough and irregular. There is a dense area along the mid superior surface. Numerous heavy trabeculae extend from there to the posterior surface of the tuber calcanei; some also extend down to the anterior inferior angle and a third group to the surface articulation with the cuboid. Another group of trabeculae forms arcs beginning at the anterior superior margin and ending at the posterior superior margin after pursuing a semicircular course which brings them close to the inferior surface. There is also a small group of trabeculae parallel to the superior surface of the tuber calcanei. A few trabeculae run parallel to the

Plate V

Figure 11

From lateral view of male foot (B)

1. Talus
2. Spur of talus
3. Calcaneus
4. Apophysis of calcaneus
5. Nutrient foramen of calcaneus
6. Nutrient foramen of calcaneus

Figure 5

From lateral view of female foot (RH)

- 1-5. as in Figure 11
6. Blood sinus
7. Trigonum

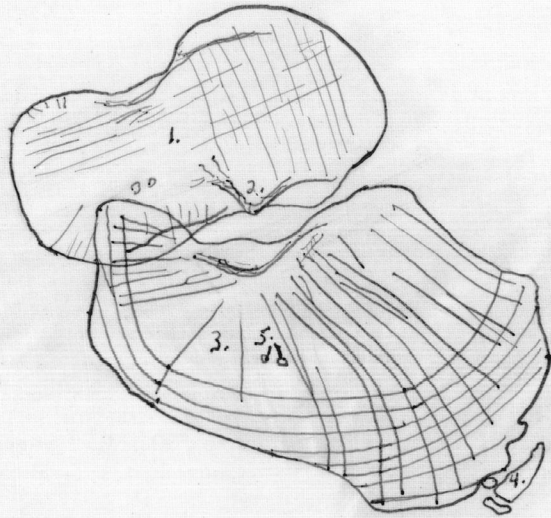


Figure 11.

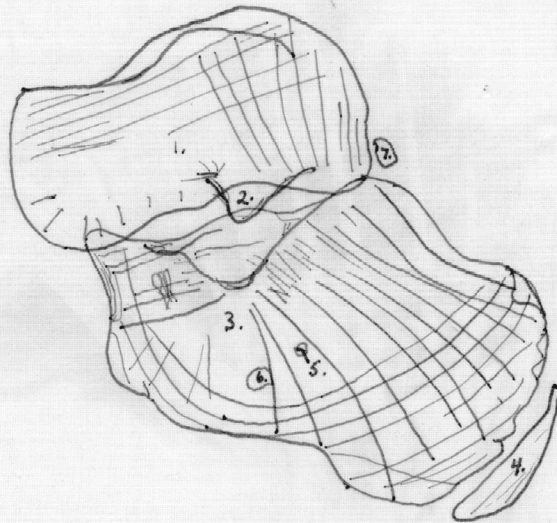


Figure 12.

inferior surface. A small circular density suggesting a nutrient foramen is seen at about the center of the calcaneus.

The apophysis is seen in a complete series from a very faint density in one male (H), through larger irregular fragmented densities in two males (E and B), crescent-shaped bodies showing some internal structure in two females (RH and M) to the most mature in one female (O) where it is a heavy crescent-shaped structure showing trabeculae parallel to the surfaces and also a few perpendicular to them. In the first mentioned it is separated from the tuber but in the last it is quite closely applied.

Discussion

The tarsals of the females are closer and better adapted to one another. Ossa trigona appeared bilaterally in one female (RH) and unilaterally in another (M). Sesamoid bones were seen in two females. The apophyses in the females are larger, denser, and have internal structure.

See Plate V, Figure 11 and 12.

General Discussion

In comparing the males with the females certain differences were seen. In general the bones of the females were better adapted to each other, especially in the wrist and ankle. They also showed better defined internal structure. More secondary centers were present in the females, especially about the elbow. Certain centers were missing in one of the males (H) but centers which usually appear later were present. It was of interest that the os trigonum which is said to appear

in 6 to 8% of all humans was present bilaterally in one female (RH) and unilaterally in one female (M).

There were a few sex differences noted. There was a greater carrying-angle in the females. The males showed a tubercle at the pubo-ischial junction while in the females there was a fusiform swelling at this point. The superior ramus of the ischium forms an angle with the inferior which is slightly more rounded in the male than in the female.

There is considerable variation in the same sex in the same age group.

The comparison of a similar series of plates of an 11 year 5 month old male shows practically the same maturation picture as a 9 year 1½ month old female (RH). The greatest difference is the greater size of the bones in the male. He also shows a notch on the radial side of the capitate which was seen in two of the younger males. There is a questionable os trigonum on the left side. The internal structure is practically identical with that of one of the females (RH).

Two incomplete series were also considered. The first was a 59 month old male and the second a 40 month old female. These are not readily compared to the 8 and 9 year old subjects. Except for greater bone size in the male those two are roughly comparable but the centers present are not the same although they are of the same sheaves.

Comments from the Literature

Growth is said not to be a smooth even process. There is usually rapid growth for about the first three years; then

it is slower until the age of 10 or 12 years; and finally there is another period of rapid growth through the time of puberty and adolescence.

Except for a period of about one month during the latter part of fetal life, when the male is in advance, the female is in the lead in development and maturation. When the female is a little over 12 years old her maturation is about that of a male of 14 years. The epiphyses of the female unite in most instances several years ahead of the epiphyses of the male.

The total number of body bones increases until puberty and then decreases to maturity. In the skull, the number of bones steadily decreases because no new or epiphysial centers appear. See Table I.

New ossification centers tend to appear in groups and the non-appearance of one center of a group is of no significance. Even the absence of an entire group does not mean that the next sheaf will not appear on schedule. Acceleration, especially local acceleration is very rare, but general retardation is less rare with local retardation more common and, when it occurs, it is more often an expression of local susceptibility rather than local damage. See Table II.

Maturity is measured, not by dimensions, but by successive changes in shaft ends or in contour of epiphyses. Appearance of centers of ossification may be used as a maturity determinant only if they are considered in groups; otherwise there are many small variations. The assessment of maturity of different regions of the same child may vary as much as 18 months.

The beginning of ossification of an epiphysis is in the center of the preformed cartilage and the first centers usually appear in the largest cartilages. This may be related to decreased blood supply, as it is known that hyperemia causes decalcification and vice versa. If there are two epiphyses on a bone, the last to ossify is the first to unite in all bones except the fibula. If there is more than one epiphysis at the same end of a bone, the epiphyses tend to unite with each other before they unite with the end of the bone. Improper ossification causes cauliflower-like densities.

Epiphyses are sometimes divided into pressure, traction, and atavistic epiphyses. Atavistic epiphyses are once independent skeletal elements which have become a part of some other element.

Stephen Hale in 1747 concluded that long bones grow at their ends after showing that small holes drilled in the shaft of a growing bone had not changed in relation to one another although the bone had increased in length. The periosteum, however, does not grow by increments from the epiphysial line but by interstitial growth throughout its entire structure. The diaphysis grows in width by surface deposits beneath the periosteum.

The shape of long bones is maintained by modelling at the ends. If there is a defect in the periosteum normal modelling does not occur and an exostosis of the unmodelled bone may result at the site of the defect. The surrounding

structures also compromise bone shapes by mere presence as well as by functional pressures. Continuous pressure causes atrophy and intermittent pressure causes hypertrophy of bone.

The traditional explanation of the form and structure of bone is that it is purely a response to mechanical stresses and strains. However, many recent workers deny this and say that the initial form and internal structure of bone is laid down before there are external mechanical factors, and that the final picture is a compromise between the initial form and the effects of mechanical stress and strain.

Modern literature presents many interesting theories of bone growth and development but there is little agreement among the various authorities even in the fundamental aspects of the problem.

TABLE I

Approximate Number of Ossification Centers and Separate Bones in the Human Skeleton at Different Ages (Sesamoid bones are omitted with the exception of the patella.)

	Skull including auditory ossicles and hyoid	Vertebral columns	Ribs and sternum	Upper Extremity	Lower Extremity	Total paired bones counted as two
Total number of centers formed	120	295	101	140	140	806
Number of centers appearing after birth	9	197	73	82	88	443
Number of separate bones at birth	45	93	34	48	50	270
Number of separate bones at fourteenth year	33	33	29	124	136	356
Number of separate bones at maturity	29	26	25	64	62	206

Taken from Abt's Pediatrics (with minor modification)

TABLE II

Times of Appearance and Union of Various Centers of Ossification

	Appear in males	Appear in females	Unite in males	Unite in females
Clavicle--2 primary	f6 w	f6 w		
sternal epiphysis	18 y	15 y	24 y	23 y
acromial epiphysis	18-19 y	18-19 y	19-20 y	19-20 y
Scapula--body	f8 w	f8 w		
first coracoid	1 y	1 y		
second coracoid	15 y	15 y		
first acromion	17 y	16 y	20-25 y	20-25 y
second acromion	18 y	17 y	20-25 y	20-25 y
inferior angle	16 y	16 y	20-21 y	20-21 y
vertebral border	17 y	17 y	20-21 y	20-21 y
Humerus--shaft	f6-8 w	f6-8 w		
head	0-3 m	0-2 m	19 $\frac{1}{2}$ -20 $\frac{1}{2}$ y	19 $\frac{1}{2}$ -20 $\frac{1}{2}$ y
greater tubercle	5-27 m	3-10 m	c head 4-5 y	c head 4-5 y
lesser tubercle	3-5 y	3-5 y	c head 4-5 y	c head 4-5 y
capitulum	1 $\frac{1}{2}$ -8 m	1-6 m)	12 y	12 y
trochlea	11-12 y	11-12 y)	c shaft at	
medial epicondyle	57 m	27-61 m)	14-15 y	14-15 y
lateral epicondyle	11 y	11 y	15-16 y	15-16 y
Ulna--shaft	f7-8 w	f7-8 w		
olecranon	8-10 y	8-10 y	14 $\frac{1}{2}$ -15 $\frac{1}{2}$ y	12 $\frac{1}{2}$ -13 $\frac{1}{2}$ y
distal epiphysis	63 m	52 m	18-19 y	18-19 y
Radius--shaft	f7-8 w	f7-8 w		
head	46 m	36 m	14 $\frac{1}{2}$ -15 $\frac{1}{2}$ y	12 $\frac{1}{2}$ -13 $\frac{1}{2}$ y
distal epiphysis	7 m	6 m	18-19 y	18-19 y
Navicular	52-65 m	38-48 m		
Lunate	42 m	36 m		
Triquetral	10-30 m	10-20 m		
Pisiform	12-13 y	9-10 y		
Greater Multangular	50-78 m	32-48 m		
Lesser Multangular	56-78 m	36-54 m		
Capitate	0-7 m	0-6 m		

	Appear in males	Appear in females	Unite in males	Unite in females
Hamate	0-7 m	0-6 m		
Metacarpals--shafts	f8-9 w	f8-9 w		
1-epiphysis	22-24 m	12-14 m	15 $\frac{1}{2}$ -16 $\frac{1}{2}$ y	15-16 y
2-epiphysis	13-18 m	10-12 m	15 $\frac{1}{2}$ -16 $\frac{1}{2}$ y	15-16 y
3-epiphysis	15-24 m	10-18 m	15 $\frac{1}{2}$ -16 $\frac{1}{2}$ y	15-16 y
4-epiphysis	16-24 m	11-18 m	15 $\frac{1}{2}$ -16 $\frac{1}{2}$ y	15-16 y
5-epiphysis	18-24 m	13-18 m	15 $\frac{1}{2}$ -16 $\frac{1}{2}$ y	15-16 y
Phalanges of hand--shafts	f8-9 w	f8-9 w		
first digit				
1-epiphysis	18-23 m	15-18 m	15-16 y	14-15 y
2-epiphysis	12-18 m	8-12 m	15-16 y	14 $\frac{1}{2}$ -15 $\frac{1}{2}$ y
second digit				
1-epiphysis	12-18 m	8-12 m	15-16 y	14 $\frac{1}{2}$ -15 $\frac{1}{2}$ y
2-epiphysis	18-24 m	13-18 m	15-16 y	14 $\frac{1}{2}$ -15 $\frac{1}{2}$ y
3-epiphysis	29-42 m	15-24 m	14 $\frac{1}{2}$ -15 $\frac{1}{2}$ y	13-14 y
third digit				
1-epiphysis	11-18 m	7-12 m	15-16 y	14 $\frac{1}{2}$ -15 $\frac{1}{2}$ y
2-epiphysis	18-24 m	12-18 m	15-16 y	14 $\frac{1}{2}$ -15 $\frac{1}{2}$ y
3-epiphysis	21-30 m	14-18 m	14 $\frac{1}{2}$ -15 $\frac{1}{2}$ y	13-14 y
fourth digit				
1-epiphysis	12-18 m	7-12 m	15-16 y	14 $\frac{1}{2}$ -15 $\frac{1}{2}$ y
2-epiphysis	18-24 m	12-18 m	15-16 y	14 $\frac{1}{2}$ -15 $\frac{1}{2}$ y
3-epiphysis	21-30 m	14-18 m	14 $\frac{1}{2}$ -15 $\frac{1}{2}$ y	13-14 y
fifth digit				
1-epiphysis	15-24 m	11-18 m	15-16 y	14 $\frac{1}{2}$ -15 $\frac{1}{2}$ y
2-epiphysis	24-40 m	15-30 m	15-16 y	14 $\frac{1}{2}$ -15 $\frac{1}{2}$ y
3-epiphysis	29-42 m	17-24 m	14 $\frac{1}{2}$ -15 $\frac{1}{2}$ y	13-14 y
Ilium	f9 w	f9 w))
Ischium	f3 m	f3 m)14-16 y)14-16 y
Pubis	f4-5 m	f4-5 m))
Femur--shaft	f7 w	f7 w		
head	2-8 m	1-6 m	17-19 y	17-19 y
greater trochanter	27-54 m	18-35 m	17-18 y	17-18 y
lesser trochanter	9-12 y	9-12 y	17-18 y	17-18 y
distal epiphysis	f30-40 w	f25-30 w	17 $\frac{1}{2}$ -18 $\frac{1}{2}$ y	17 $\frac{1}{2}$ -18 $\frac{1}{2}$ y
Patella	32-76 m	20-40 m		
Tibia--shaft	f7 w	f7 w		
proximal epiphysis	f10 m	f9 m	17 $\frac{1}{2}$ -18 $\frac{1}{2}$ y	17 $\frac{1}{2}$ -18 $\frac{1}{2}$ y
distal epiphysis	7-21 m	5-13 m	15 $\frac{1}{2}$ -16 $\frac{1}{2}$ y	14 $\frac{1}{2}$ -15 $\frac{1}{2}$ y
Fibula--shaft	f8 w	f8 w		
proximal epiphysis	27-65 m	20-50 m	17 $\frac{1}{2}$ -18 $\frac{1}{2}$ y	17 $\frac{1}{2}$ -18 $\frac{1}{2}$ y
distal epiphysis	7-21 m	5-13 m	15 $\frac{1}{2}$ -16 $\frac{1}{2}$ y	14 $\frac{1}{2}$ -15 $\frac{1}{2}$ y

Table 2 cont'd 3

Calcaneus--body	f5 m	f5 m		
apophysis	8-10 y	8-10 y	14 $\frac{1}{2}$ -15 $\frac{1}{2}$ y	13-14 y
Navicular	21-36 m	14-24 m		
Cuboid	f10 m	f10 m		
First Cuneiform	18-30 m	9-18 m		
Second Cuneiform	20-36 m	14-18 m		
Third Cuneiform	2-6 m	2-6 m		
Metatarsals--shafts	f7 w	f7 w		
1-epiphysis	22-26 m	14-18 m	15-16 y	14-15 y
2-epiphysis	26-30 m	19-24 m	15-16 y	14-15 y
3-epiphysis	35-42 m	22-30 m	15-16 y	14-15 y
4-epiphysis	39-48 m	26-30 m	15-16 y	14-15 y
5-epiphysis	44-52 m	29-40 m	15-16 y	14-15 y
Phalanges of foot--shafts				
	f3 m	f3 m		
first digit				
1-epiphysis	21-27 m	14-21 m	14 $\frac{1}{2}$ -15 $\frac{1}{2}$ y	13-14 y
2-epiphysis	11-18 m	7-12 m	14-15 y	12 $\frac{1}{2}$ -13 $\frac{1}{2}$ y
, second digit				
1-epiphysis	14-18 m	10-12 m	14 $\frac{1}{2}$ -15 $\frac{1}{2}$ y	13-14 y
2-epiphysis	15-18 m	10-12 m	14-15 y	12 $\frac{1}{2}$ -13 $\frac{1}{2}$ y
3-epiphysis	44 m	26 m	14-15 y	12 $\frac{1}{2}$ -13 $\frac{1}{2}$ y
third digit				
1-epiphysis	13-18 m	8-12 m	14 $\frac{1}{2}$ -15 $\frac{1}{2}$ y	13-14 y
2-epiphysis	16-22 m	10-18 m	14-15 y	12 $\frac{1}{2}$ -13 $\frac{1}{2}$ y
3-epiphysis	43-50 m	23-36 m	14-15 y	12 $\frac{1}{2}$ -13 $\frac{1}{2}$ y
fourth digit				
1-epiphysis	14-18 m	9-12 m	14 $\frac{1}{2}$ -15 $\frac{1}{2}$ y	13-14 y
2-epiphysis	16-22 m	10-18 m	14-15 y	12 $\frac{1}{2}$ -13 $\frac{1}{2}$ y
3-epiphysis	43-50 m	24-36 m	14-15 y	12 $\frac{1}{2}$ -13 $\frac{1}{2}$ y
fifth digit				
1-epiphysis	21-30 m	14-21 m	14 $\frac{1}{2}$ -15 $\frac{1}{2}$ y	13-14 y
2-epiphysis	"60 m plus"	"60 m plus"	14-15 y	12 $\frac{1}{2}$ -13 $\frac{1}{2}$ y
3-epiphysis	40-50 m	21-30 m	14-15 y	12 $\frac{1}{2}$ -13 $\frac{1}{2}$ y

y--year or years
 f--fetal
 w--week or weeks
 m--month or months

Compiled from:
 Abt, I. A.
 Francis, C. C. and
 P. P. Weorle
 Gray, Henry
 Hill, A. H.
 Pryor, J. W.
 Rauber and Kopsch
 Todd, T. W.
 Vogt, E. C. and
 V. S. Vickers

BIBLIOGRAPHY

1. Abt, I. A. Pediatrics (by various authors) Vol. I
Chapt. III. A Summary of the Anatomy of the Infant and
Child. 257-295. Philadelphia 1923.
2. Adams, C. O. and E. L. Compere. Studies in longitudinal
growth in long bone. Journal of Bone and Joint Surgery:
19: 922-936. Oct. 1937.
3. Appleton, A. B. Postural Deformities in Bone Growth.
Lancet: 112: 451-454. Mar. 3, 1934.
4. Banks, S. W., William Krigsten, and E. L. Compere. Regen-
eration of Epiphyseal Centers of Ossification. Journal
of the American Medical Association: 114: 23-26.
Jan. 6, 1940.
5. Bisgard, J. D. and M. E. Bisgard. Growth of Long Bones.
Archives of Surgery: 31: 568-578. Oct., 1935.
6. Brach, J. C. Some Problems of Growth and Development of
Mechanics in Bone. Edinborough Medical Journal:
41: 305-319, and 363-385. May and June, 1934.
7. Bryce, T. H. Quain's Anatomy. Vol. 4: part 1. Osteology
and Arthrology: 135-210. London. 1915.
8. Clark, W. E. LeGros. The Tissues of the Body. 55-95.
London. 1939.
9. Dwight, Thomas. Variations in the Bones of the Hands and
Feet. Phila. 1907.
10. Francis, C. C., and P. P. Werle. The Appearance of Centers
of Ossification from Birth to Five Years. American
Journal of Physical Anthropology: 24: 273-299. Mar., 1939.
11. Gray, Henry. The Anatomy of the Human Body. 23 ed.
Edited by Warren Lewis: 192-269. Phila. 1936.
12. Hill, A. H. Fetal Age Accesment by Centers of Ossifica-
tion. American Journal of Physical Anthropology:
24: 251-272. Mar., 1939.
13. Howell, J. A. An Experimental Study on the Effects of
Stress and Strain in Bone Development. Anatomical
Record: 13: 233-252. Oct., 1917.
14. Jones, R. W. and R. E. Roberts. Calcification, Decalci-
fication and Ossification. British Journal of Surgery:
21: 461-499. Jan., 1934.

15. Keith, A. Studies on Anatomical Changes which accompany Certain Growth Disorders. *Journal of Anatomy*: 54: 101-115. Apr., 1920.
16. Koch, J. C. Laws of Bone Architecture. *American Journal of Anatomy*: 21: 177-298. Mar., 1917.
17. Laidlaw, P. P. The Varieties of Os Calcis. *Journal of Anatomy and Physiology*: 38: 133-143. Jan., 1904.
18. Idem. Os Calcis Part II. *Journal of Anatomy and Physiology*: 39: 161-177. Jan., 1905.
19. LeRiche, R. and A. Policard. The Normal and Pathological Physiology of Bone. St. Louis. 1928.
20. Mall, F. P. On Measuring Human Infants. *Anatomical Record*: 1: 129-140. Aug., 1908.
21. Murray, P. D. F. Bones. London. 1936.
22. Parsons, F. G. Observations on Traction Epiphyses. *Journal of Anatomy*: 38: 248-258. Apr., 1904.
23. idem. Further Remarks on Traction Epiphyses. *Journal of Anatomy*: 42: 388-396. 1908.
24. idem. On the Meaning of some of the Epiphyses of the Pelvis. *Journal of Anatomy*: 37: 315-323. July, 1903.
25. Peter, Karl, George Wetzel and Friedrich Heiderich. *Handbuch der Anatomie des Kindes. Zweiter Band*: 403-577. Munich. 1938.
26. Pryor, J. W. Difference in Time of Development of Centers of Ossification in Male and Female Skeleton. *Anatomical Record*: 25: 257-268. June, 1923.
27. idem. Roentgenographic Investigation of Time Element in Ossification. *American Journal of Roentgenology*: 29: 798-804. June, 1933.
28. Rauber and Kopsch. *Lehrbuch und Atlas der Anatomie des Menschen. Abteilung. 2: Knochen-Bänder*. By F. Kopsch: 222-229. Leipzig. 1932.
29. Selye, H. On Mechanism Controlling the Growth in Length in Long Bones. *Journal of Anatomy*: 68: 289-292. Apr., 1934.
30. Sewell, R. B. S. A Study of the Astragalus. Part I. *Journal of Anatomy and Physiology*: 38: 233-247. Apr., 1904.

31. idem. A Study of the Astragalus. Part II. Journal of Anatomy and Physiology: 38: 423-434. July, 1904.
32. idem. A Study of the Astragalus. Part III. Journal of Anatomy and Physiology: 39: 74-88. Oct., 1904.
33. Sullivan, W. E., F. D. Geist and G. G. Mueller. The Epiphyses of the Bones of the Extremities at Puberty. Journal of Bone and Joint Surgery: 6: 239-261. Apr., 1924.
34. Todd, T. W. Age Changes in the Pubic Bone. American Journal of Physical Anthropology: 14: 255-271. Apr.-June, 1930.
35. idem. Anatomical Features of Epiphyseal Union. Child Development: 1: 186-194. Sept., 1930.
36. idem. Atlas of Skeletal Development. (Hand) St. Louis. 1937.
37. Vogt, E. C. and V. S. Vickers. Osseous Growth and Development. Radiology: 31: 441-444. Oct., 1938.
38. Warwick, W. T. and P. Wiles. Growth of Periosteum in Long Bones. British Journal of Surgery: 22: 169-174. July, 1934.

Approved

Walter Sullivan

March 1, 1940.